A visual guide to surface anatomy

General Anatomy

Andreas Syrimis
Senior lecturer University of Westminster

The joints

Author: Andreas Syrimis
Graphic design and photography: Annabel King, Pascalis Spyrou
Clinical editors: Charles Goillandeau, Claire Rother, Katie Stock, Euan MacLennan
Produced in collaboration with the University of Westminster and Bloomsbury Educational Ltd.

The joints

❑ The joints of the upper limbs

- The sternoclavicular joint
- The acromioclavicular joint
- The shoulder joint
- The elbow joint
- The proximal radio-ulnar joint
- The distal radio-ulnar joint
- The wrist and radio-carpal joint
- The intercarpal joints
- The carpo-metacarpal joints
- The Metacarpo-Phalangeal Joints
- The Inter-Phalangeal Joints

Video resources

The joints:
https://www.youtube.com/watch?v=kDDnLficEio&t=23s

THE JOINTS

The upper limbs

		Page No.
1.	How do you locate the sternoclavicular joint?	44
2.	How do you locate the acromioclavicular joint?	44
3.	Describe the glenohumeral joint.	44
4.	Describe the humero-ulnar part of the elbow joint.	44
5.	Where is the joint line of the humero-ulnar joint located?	45
6.	Describe the proximal radioulnar joint.	45
7.	How is the proximal radioulnar joint palpated?	45
8.	Describe the distal radioulnar joint.	45
9.	How is the distal radioulnar joint palpated?	45
10.	Describe the anatomical location of the styloid process of the radius.	45
11.	Describe the structure of the wrist and radiocarpal joint.	46
12.	Where is the wrist joint located and how is this articulation palpated?	46
13.	Describe carpal bones and the articulations of the intercarpal joints.	46
14.	Describe the carpo-metacarpal joints.	46
15.	What is the approximate distance of the carpo-metacarpal joints from the wrist line.	46
16.	Describe the uniqueness of the first carpo-metacarpal joint.	46
17.	How is the first carpo-metacarpal joint palpated?	46
18.	Describe the metacarpo-phalangeal joints?	47
19.	How is the first metacarpo-phalangeal joint orientated in relation to the other metacarpo-phalangeal joints?	47 47
20.	Describe the interphalangeal joints.	47
21.	What is different in the interphalangeal joints of the first digit?	47

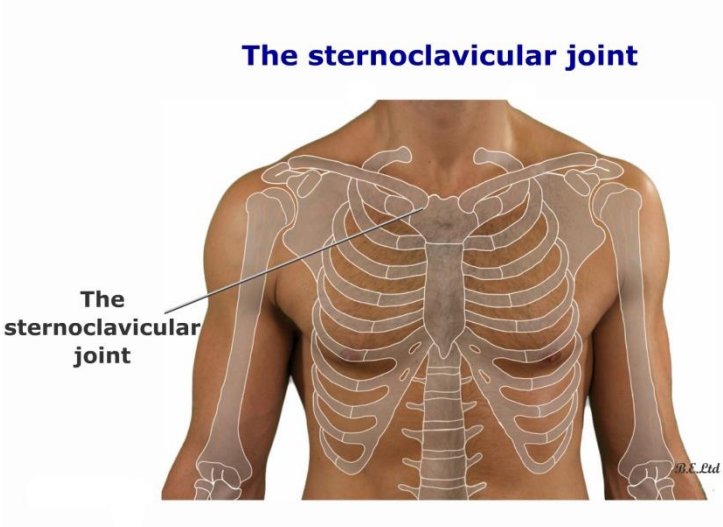

The Sternoclavicular Joint

- This is a synovial saddle joint formed by the medial end of the clavicle with the manubrium. An articular disc separates the two articular surfaces.
- The clavicular notch of the manubrium is located superolaterally on either side of the depression of the sternal notch.
- The joint can be identified by moving the clavicle superiorly and inferiorly by elevating and depressing the shoulder complex.
- Alternatively ask the subject to protract and retract the shoulders.

The Acromioclavicular Joint

- This is formed by the distal end of the clavicle with the acromion. It is about 2cm medially from the most lateral part of the acromion.
- The spine of the scapula as it travels laterally becomes thickened and more prominent, turning anteriorly and slightly medially to become the acromion.
- Although it is a plane synovial joint it permits very little movement and therefore difficult to palpate unless pressure is exerted either on the clavicle or on the acromion.

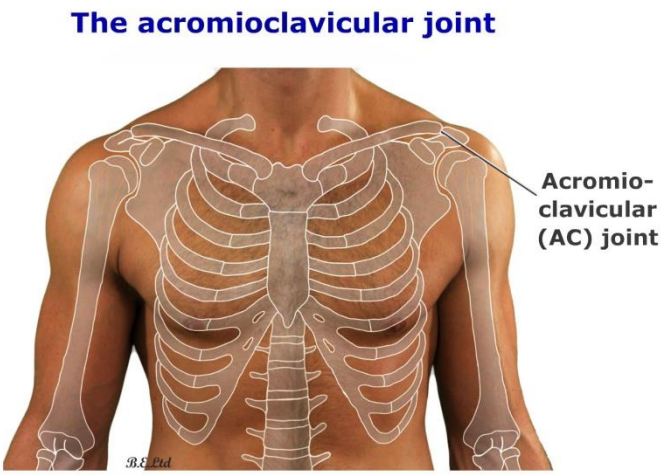

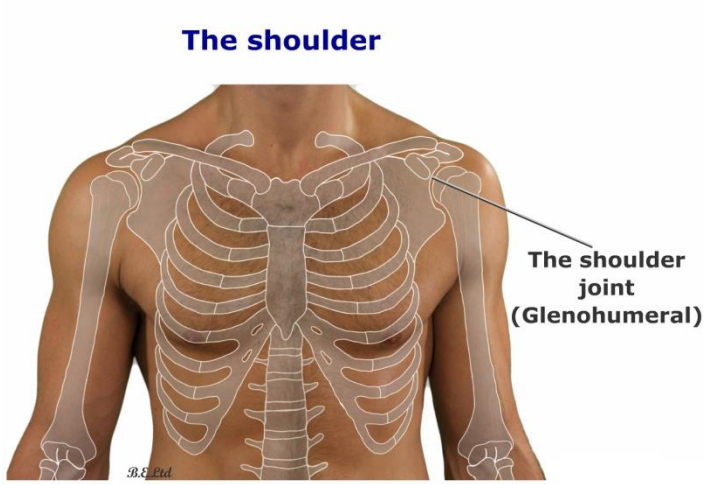

The Shoulder Joint

- More specifically, the glenohumeral joint is a synovial ball-and-socket joint. It is formed by the shallow glenoid fossa on the lateral and superior part of the scapula and the head of the humerus.
- The joint lies deep within muscles and ligaments of the pectoral girdle and thus not easy to palpate.
- The proximal part of the humerus has the greater and lesser tuberosities which protrude in a superior direction. Axial rotation of the humerus makes this area palpable. A slight depression below the arch of the acromion marks the position of the superior part of the head of the humerus.

The Elbow Joint

- Like the shoulder this is a collective name for several articulations. The humero-ulnar joint is a synovial hinge joint located in the medial part of the elbow. The trochlea of the humerus articulates with the trochlea notch of the ulna.
- The joint line is about 2cm below the medial epicondyle of the humerus.
- The anterior part of the humero-ulnar joint is not palpable due to muscles overlying it.
- Posteriorly the olecranon, a proximal projection of the ulna can be palpated with ease when the arm is flexed to 90^0.

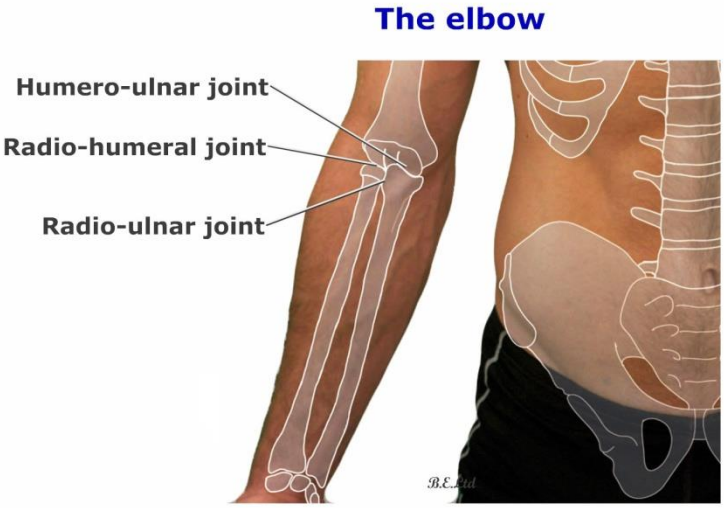

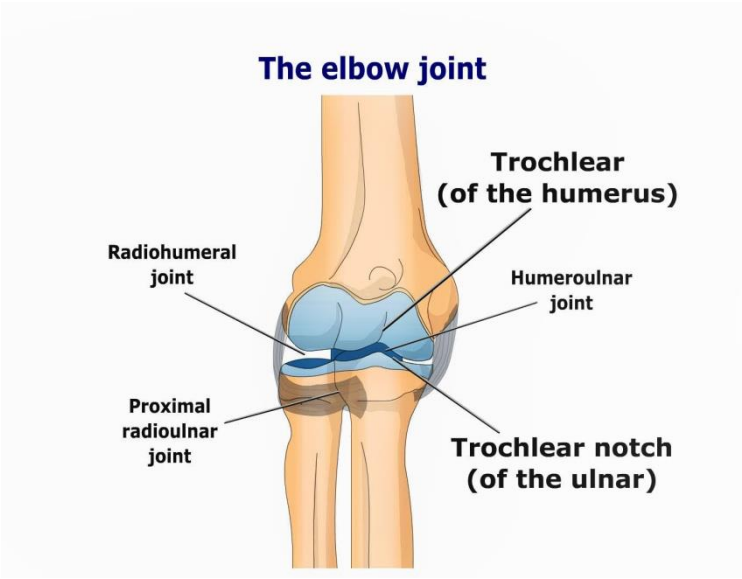

The Proximal Radioulnar Joint

- The proximal radio-ulnar joint is a synovial pivot type enabling the forearm to pronate and supinate. The neck of the radius contains the annular ligament. The superior surface of the head of the radius articulates with capitulum of the ulna.
- The head of the radius may be palpated on the lateral part of the supinated forearm about 1cm distal to the joint line of the humero-ulnar joint.
- Use a gripping hold with thumb and index finger whilst pronating and supinating the forearm

The Distal Radioulnar Joint

- This is also a pivot joint but without the distinct head of the proximal radioulnar joint. Conversely the distal head of the ulna is more cylindrical. The joint line is about 1cm above the line of the wrist. The styloid process of the ulna and radius may be used as landmarks.
- The radial stylus is about 1cm lower than its ulnar counterpart. The distal head of the radius is broader forming the largest articulation with the proximal carpal row.
- The joint line may be felt during flexion and extension. However the joint line cannot be felt during pronation and supination as the whole wrist follows the movement of the distal radio-ulnar joint.

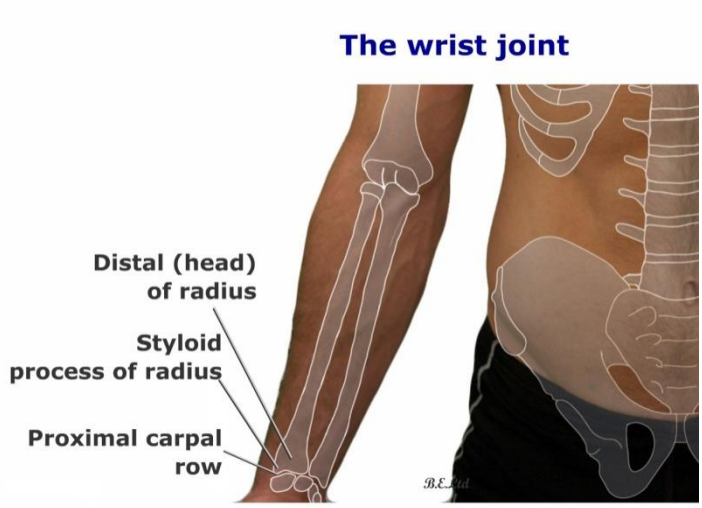

The Wrist and Radio-Carpal Joint

- This is an ellipsoid joint formed by the radius and the proximal row of carpal bones. The carpal bones on the ulnar side only make indirect contact with the triquetral via the articular disc during ulnar deviation.

- The radiocarpal joint is made up of the distal end of the radius with an articular disk separating it from the scaphoid, lunate, and triquetral bones.

- Find the styloid process of the radius and progress towards the centre of the wrist line. Feel its principal movements, flexion, extension, medial and lateral deviation. With the right grip above and below you can also assess distraction.

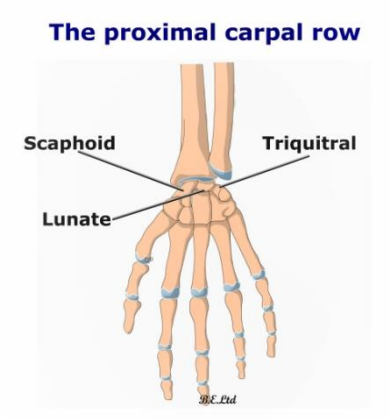

The Intercarpal Joints

- There are several synovial plane articulations between the carpal bones. Movement is not easy to detect due to tight ligamentous stability.

The Carpo-Metacarpal Joints

- These are the articulations between the distal carpal row and the long metacarpals. The joints are roughly 2cm distal to the wrist joint. The second to fifth joints are synovial ellipsoid joints with a nominal degree of movement.

- However, the 1st carpo-metacarpal joint of the thumb exhibits great range of movement. The trapezium forms a saddle synovial articulation with the 1st proximal phalanx.

- To feel the movement grip the distal end of the 1st metacarpal and move the thumb in all planes.

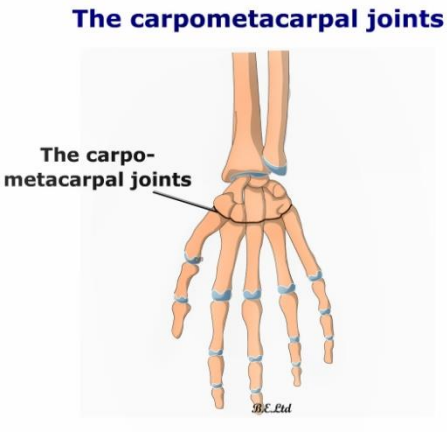

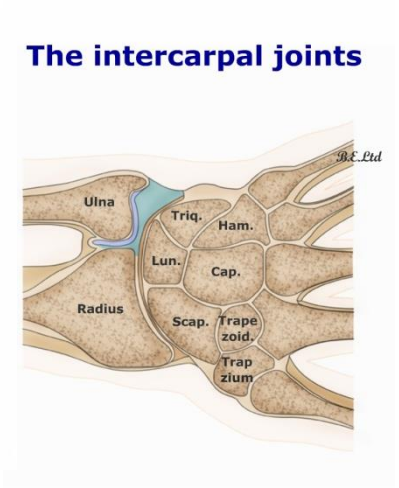

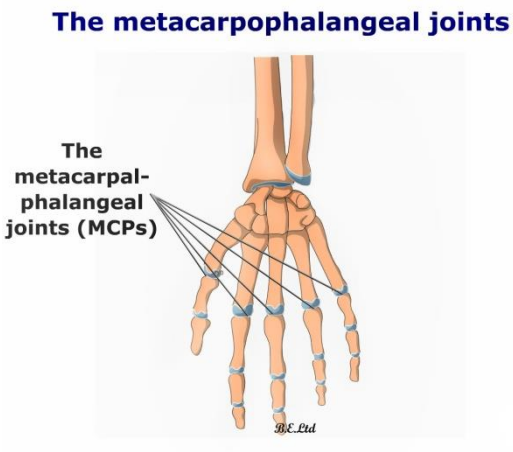

The Metacarpo-Phalangeal Joints

- These are synovial condyloid or ellipsoid joints, formed by the rounded heads of the metacarpal bones with the shallow cavities on the proximal end of the phalanges, with the exception of that of the thumb.
- The former are capable of 90^0 flexion. Making a fist makes these articulations prominent with the 3rd MCP joint usually more prominent.
- The MCP joint of the thumb is orientated at right angle to the other MCPs and only able to do 45^0 flexion.

The Inter-Phalangeal Joints

- The interphalangeal articulations of the hand are synovial hinge joints between the phalanges.
- There are two sets of joints (except in the thumb): "the proximal interphalangeal joints" (PIPs), are those between the proximal and intermediate phalanges "the distal interphalangeal joints" (DIPs), are those between the intermediate and distal phalanges.
- As the thumb only has two phalanges it only has one interphalageal joint. They are all capable of 90^0 flexion.

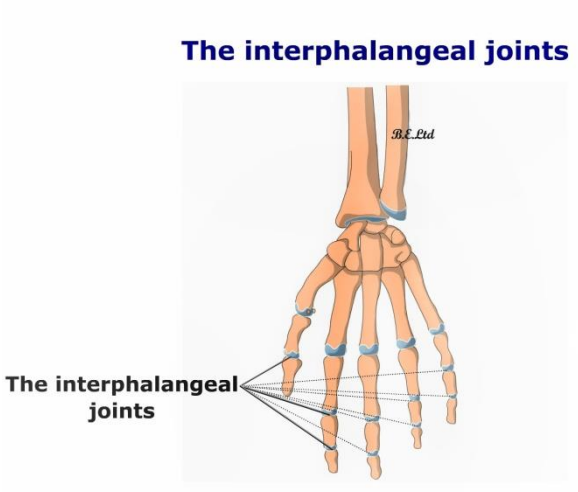

The joints of the Axial Skeleton

❑ Joints of the Axial Skeleton

- The Manubriosternal Joint or the Angle of Lewis
- The costochondral joints
- The sternocostal joints
- The 1st and 2nd sternocostal joints
- The costal cartliges of ribs 8,9 and 10
- The costovertebral joints
- The costotransverse joints
- The symphysis pubis

Assessment questions

JOINTS OF THE AXIAL SKELETON	Page No.
1. Describe the manubriosternal joint or angle of Lewis.	50
2. What is the relationship of this joint to the sternocostal joints?	50
3. Describe the nature of the costochodral joints.	50
4. Describe the structure of the costochondral joints of ribs 1-5.	50, 51, 32
5. Describe the structure of the costochondral joints of ribs 6-9.	50, 51, 32
6. Describe the articulation between of ribs 9 and 10.	51
7. What is the approximate length of the costal cartilages of ribs of the upper, middle and lower ribs?	50
8. Describe the sternocostal joints.	50
9. How is the first sternocostal joint different from the rest?	50-51
10. Describe the sternocostal articulations of ribs 1-7.	51
11. Describe the articulations of ribs 8,9 and 10.	51
12. Describe the costovertebral joints and their articulations.	52
13. Describe the costotransverse joints and their articulations.	52
14. Is it possible to palpate the costovertebral and costotransverse joints?	52
15. Describe the structure of the symphysis pubis.	53
16. Describe the relationship of the urinary bladder with the symphysis pubis.	53

The Manubriosternal Joint or the Angle of Lewis

- In most subjects this marks is a horizontal elevated ridge on the superior part of the sternum appx 4cm below the suprasternal notch. Roll your fingertips or glide them over the skin to feel the joint line.
- On either side of the joint is the sternocostal union of the 2nd costal cartilage, a useful landmark for orientation over the thorax.

The manubriosternal joint

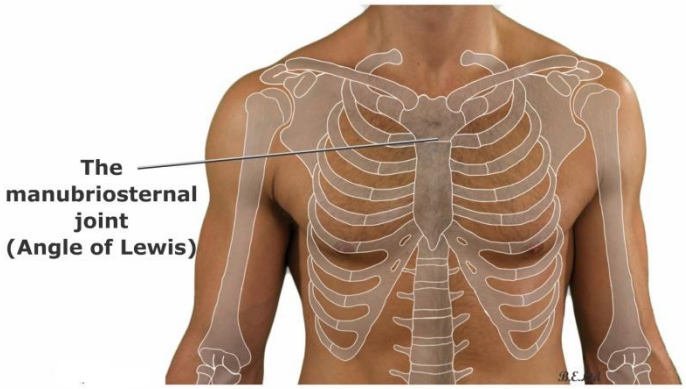

The costochondral joints

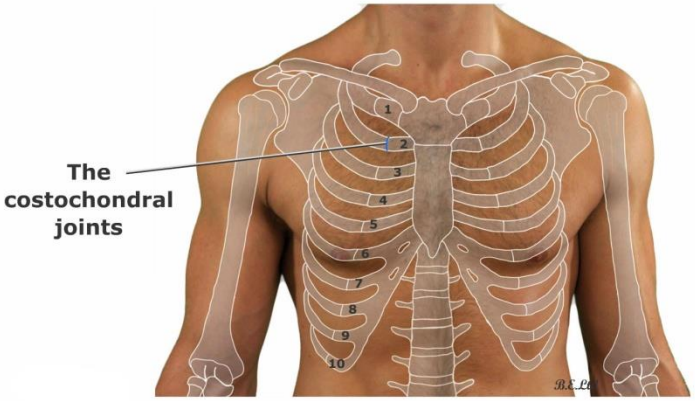

The cartilaginous component of the ribs

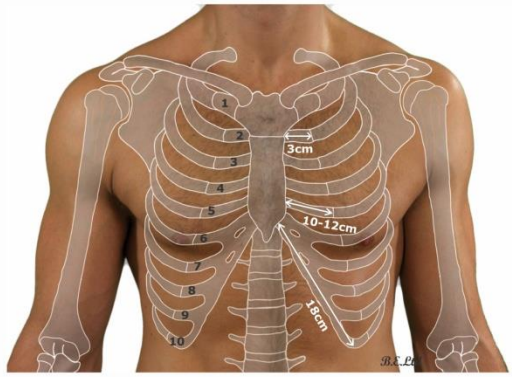

The Costochondral Joints

- This is the union of the bony component of each rib with their cartilaginous counterpart.
- These are not usually palpable depending on the individual's morphology. They are hyaline cartilagenous joints. Each rib has a depression shaped like a cup that the costal cartilage articulates with. There is normally no movement at these joints.
- Joints between costal cartilages of ribs 6-9 are plane synovial joints.
- Articulation between costal cartilage of rib 9 and rib 10 are fibrous. The cartilage component in the upper ribs is much smaller whilst in the lower ribs longer.
- Therefore the costochondral joints range in distance from the sternum, appox 3cm for the 1st and 2nd ribs, 10-12cm for the middle section and18cm for rib 10.

The Sternocostal Joints

- These refer to the joints between the costal cartilages and the sternum. Articulations of the cartilages of the true ribs with the sternum are arthrodial joints, with the exception of the first rib.
- In the 1st rib the cartilage is directly united with the sternum. It is therefore, a synarthrodial articulation or primary cartilaginous joint.

The sternocostal joints

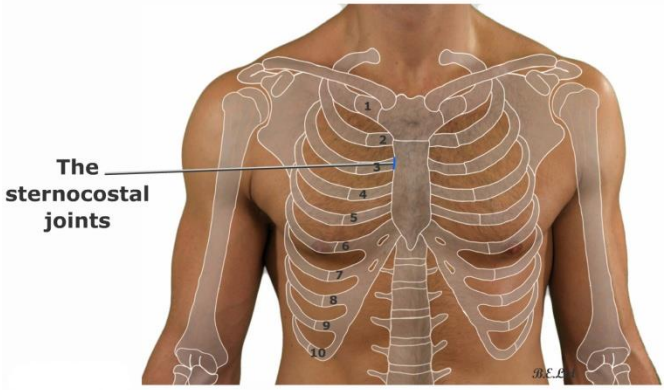

The Costal Cartilages

- In the anterior thoracic wall the costal cartilages of ribs 1-5 are almost horizontal as they approach the sternum.
- The costal cartilages of ribs 6 to 10 take an increasingly superior direction towards the inferior parts of the sternum.
- The costal cartilages of ribs 8, 9 and 10 unite together into one process to attach just lateral to the xyphosternal joint.
- To identify the ribs posteriorly you can follow some key landmarks. You can position the patient prone in a slightly flexed position. Alternatively in the sitting or standing position with the scapulae protracted and in slight flexion.

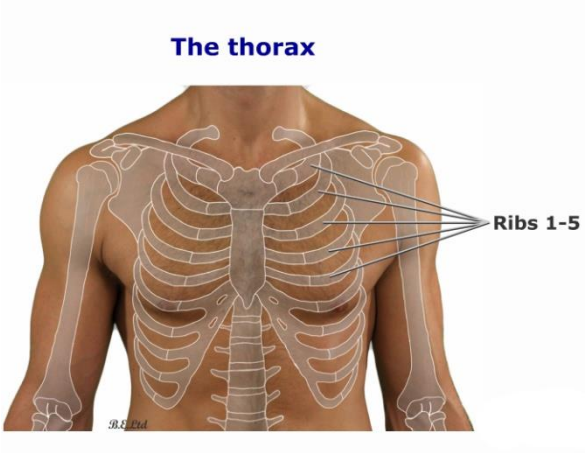

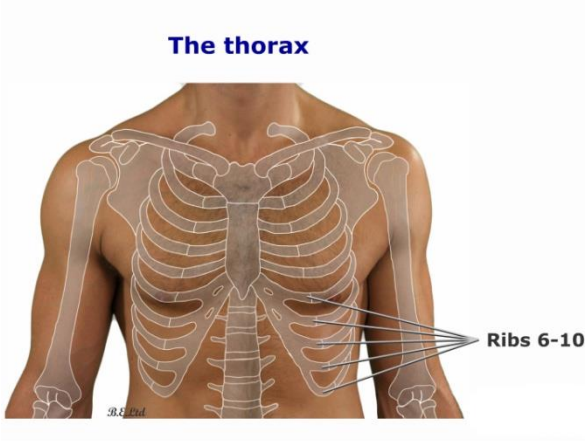

The Ribs

- The ribs can be palpated with variable ease depending on the subject's morphology.
- Posteriorly the ribs of the upper part of the thorax travel laterally in a horizontal direction until the lateral chest.
- From here they turn in an anterior and obliquely inferior direction towards their costal cartilages.
- In the inferior part of the thorax the ribs assume a slightly downward direction as they travel towards a lateral and anterior direction until their costal cartilages.
- Articulation between costal cartilage of rib 9 and rib 10 are fibrous. The cartilage component in the upper ribs is much smaller whilst in the lower ribs longer. Therefore the costochondral joints range in distance from the sternum, appx 3cm for the 1st and 2nd ribs, 10-12cm for the middle section and18cm for rib 10.

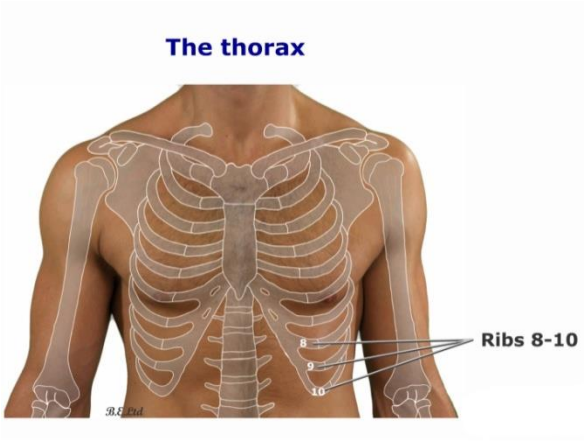

The First and Second Sternocostal Joint

- The sternocostal joint of the first rib is deep and just inferior to the sternoclavicular joint. It permits very little movement.
- The second costal cartilage is attached to the manubriosternal joint which is in a slight recession in relation to the 1st and 3rd sternocostal joints.

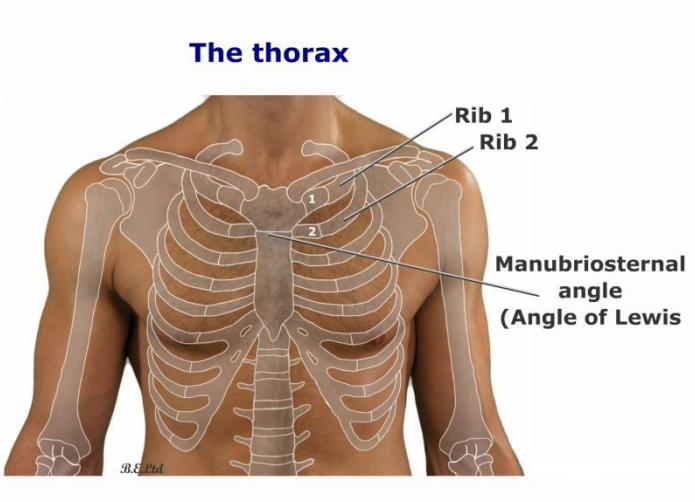

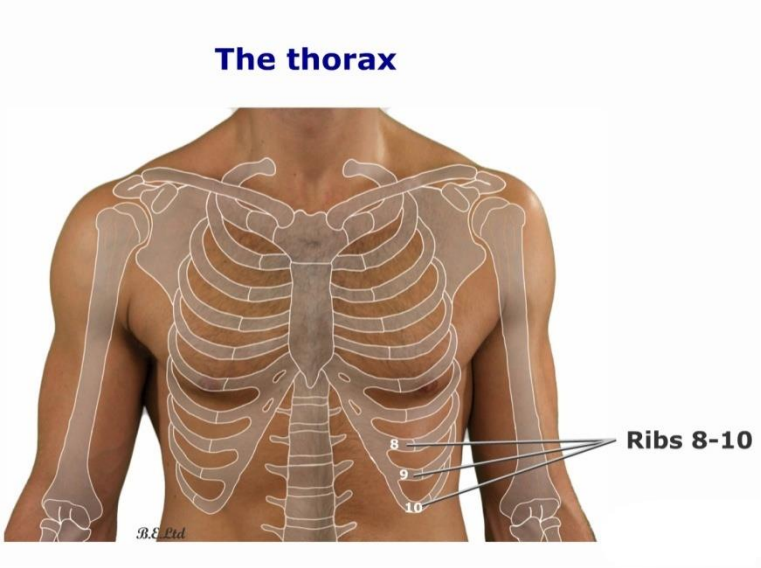

The Costal Cartilages of Ribs 8, 9 and 10

- The direct sternocostal connections only go as far as rib 7. The costal cartilages of ribs 8, 9 and 10 articulate with each other forming interchondral synovial joints.
- If the lower border of these articulations is followed laterally they form the subcostal angle.

The Costovertebral Joints

- These are the articulations that connect the heads of the ribs with the bony bodies of the thoracic vertebrae. Each rib head has two convex facets.
- These facets articulate with the bodies of two adjacent vertebrae.

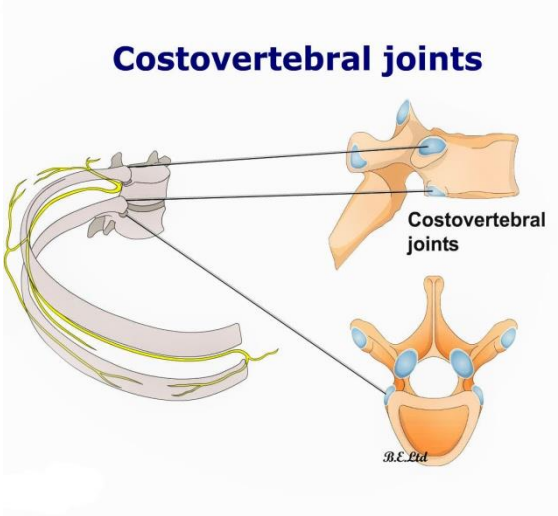

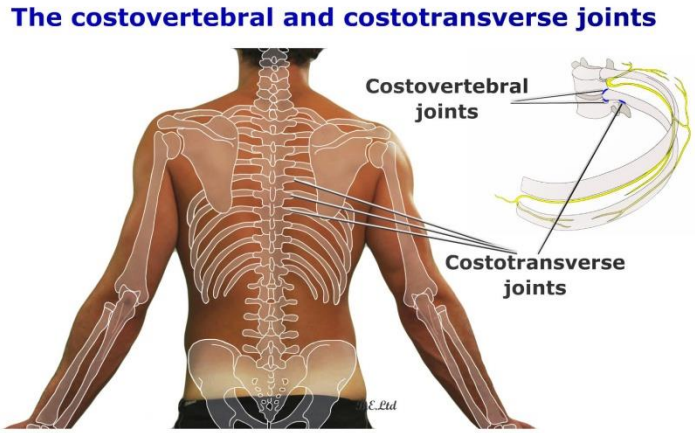

The Costotransverse Joints

- Each rib also articulates with the transverse process of the respective vertebra via small synovial facet joints.
- Posteriorly the costotransverse joints may be palpated indirectly lying in the paravertebral depression

The symphysis pubis

- The symphysis pubis is a midline union of the anterior bony pelvis formed by the pubic bones.
- This forms the anterior articulation of the pelvic girdle, uniting the superior rami of the left and right pubic bones. The posterior articulation being the sacroiliac joints. It is a secondary cartilaginous joint.
- It is located anterior to the urinary bladder and superior to the external genitalia; for females it is above the vulva and for the males it is above the penis.
- The superior surface of the pubic bone can be traced medially until the pubic tubercles are felt.
- The brim of the true pelvis is roughly 4cm above the genitalia.
- Between the left and right tubercles a small depression signifies the cartilage and intra-articular disk.

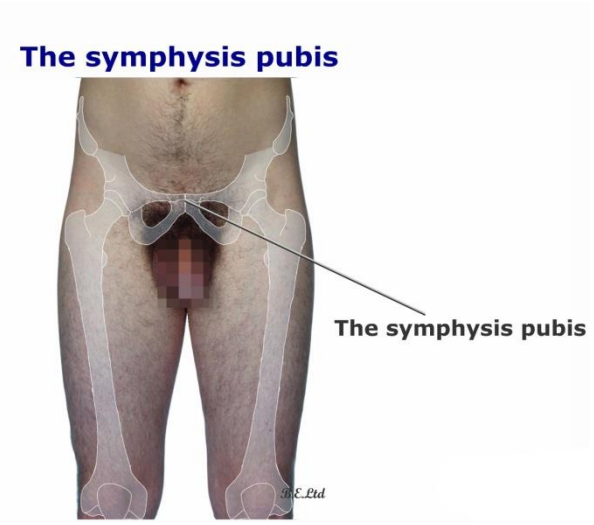

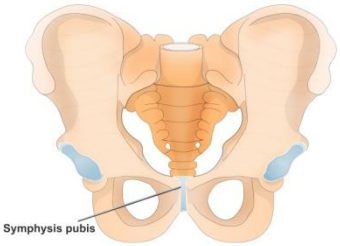

The Urinary Bladder

- The urinary bladder is located just posterior and superior to the symphysis. The external genitalia are just below the symphysis pubis. To relax the abdominal wall place your subject in a supine position with the knees in slight flexion.
- The pubic tubercles can be palpated on either side of the midline cartilage.
- The rest of the pubic ramus can be traced laterally with your fingertips by tracing the bony margin feeling and the soft abdominal wall above, eventually curving upwards towards the ilium.

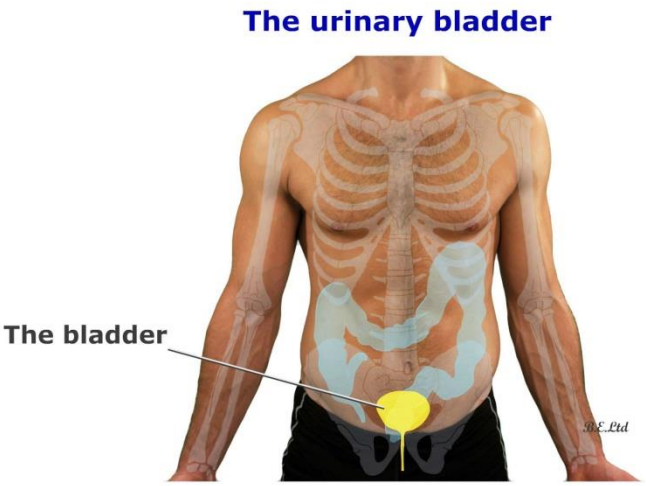

The joints of the lower limbs

❑ Joints of the lower limbs

- The hips
- The tibio-femoral or knee joint
- The patello-femoral joint
- The superior tibiofibular joint
- The inferior tibiofibular joint
- The tibiotalar joint
- The talonavicular joint
- The metatarsal-phalangeal joint of the big toe

JOINTS OF THE LOWER LIMBS	Page No.
• Describe the hip joints.	56
• What are the landmarks for locating the hip joints?	56
• Describe the structure of the knee joints.	56
• How do you locate the joint line of the knees?	56
• Where are the lateral and medial femoral condyles located?	56
• Where are the lateral and medial femoral epicondyles located?	56
• Describe the patellofemoral joint.	56
• Is the patella tendon and ligament relaxed when the knee is fully flexed or fully extended?	56
• Describe the superior tibiofibular joint.	57
• Where is the superior tibiofibular joint located?	57
• Which structure do you need to move in order to palpate the movement of the superior tibiofibular joint?	57
• Describe the inferior tibiofibular joint.	57
• Where is the inferior tibiofibular joint located?	57
• Describe the tibiotalar joint.	57
• Where is the inferior tibiotalar joint located?	57
• How should you position the foot in order to expose part of the superior articular surface of the talus?	57
• Describe the talonavicular joint.	58
• Where is the talonavicular joint located?	58
• Describe the metatarsal-phalangeal joints.	58
• Where is the metatarsal-phalangeal joints located?	58
• What is different in the metatarsal-phalangeal joint?	58

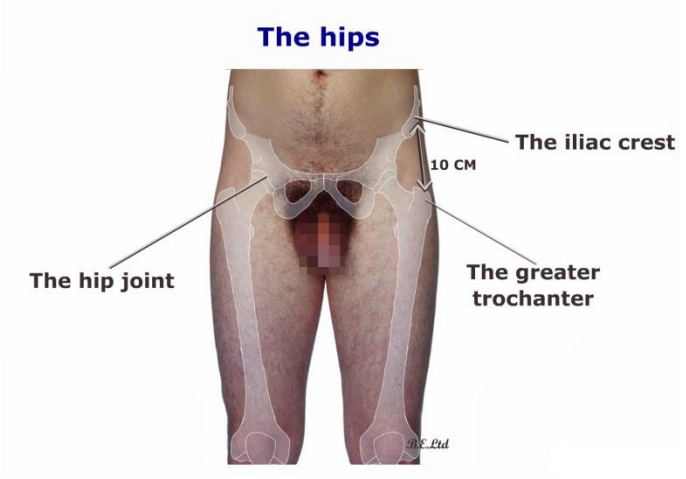

The Hips

- The hips are analogous to the glenohumeral joints both being ball-and-socket in type but with the hips being much more congruent and stable.
- The hip joints are located lateral to the gluteal region, inferior to the iliac crest, and overlying the greater trochanter of the femur.
- Unlike the glenohumaral joint the hip is shielded by the thickness of the gluteal muscles.
- The greater trochanter is about 10cm distal the iliac crest. The head of the femur in relation to the greater trochanter is located superomedially.

The Tibiofemoral or Knee Joint

- This is a synovial condyloid hinge-like joint, which permits flexion and extension as well as slight medial and lateral rotation.
- Locate the two large rounded condyles and epicondyles of the femur. With the knee flexed to 90^0 part of the condyles may be palpated on either side of the patella.
- Then locate the tibial condyles below. The joint line of the knee, that is the area between the femoral and tibial condyles can be identified by a soft depression on either side of the inferior part of the patella when the knee is in 90^0 flexion.

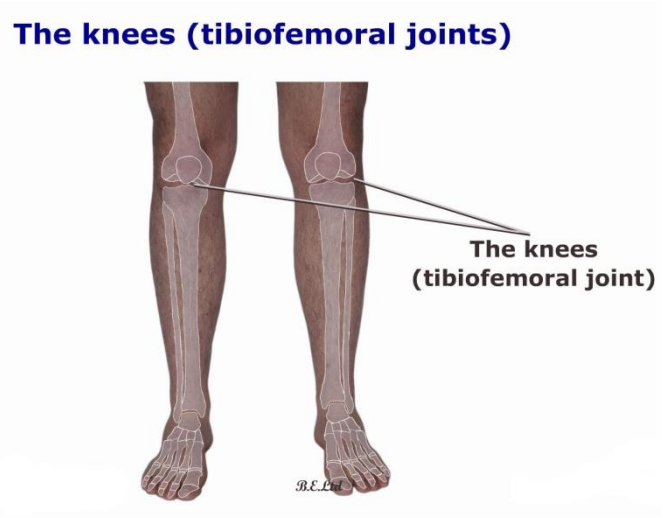

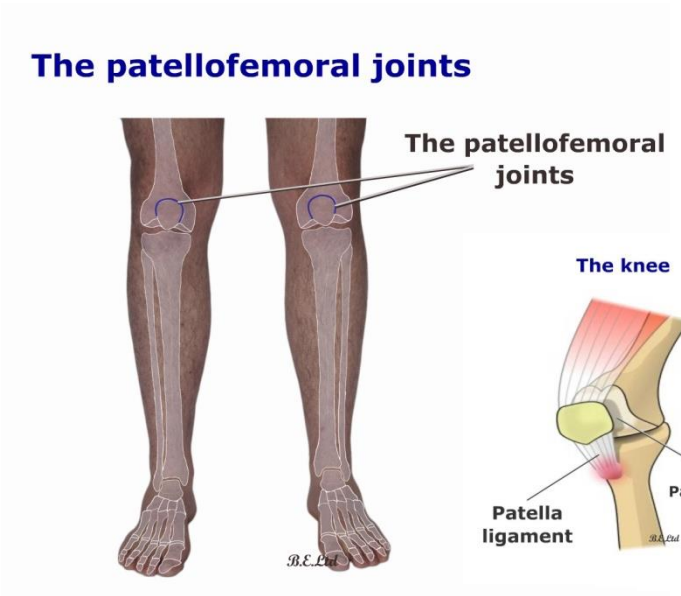

The Patello-Femoral Joint

- This is a gliding surface between the posterior surface of the patella and the femoral trochlea, an area between the lateral and medial ridges of the anterior femoral condyles.
- Only the peripheral margins of the patellofemoral articulation can be palpated. To take the tension off the patella tendon and ligament have the knee fully extended.

The Superior Tibiofibular Joint

- This is a synovial joint between the lateral condyle of the tibia and the head of the fibula.
- The fibula head is located posterolateral to the tibial condyle about 1-2 cm below the margin of the tibial plateau.
- Movement of the superior tibiofibular joint can be demostrated with the foot taken in full plantarflexion then dorsiflexion. It permits very limited gliding movement.

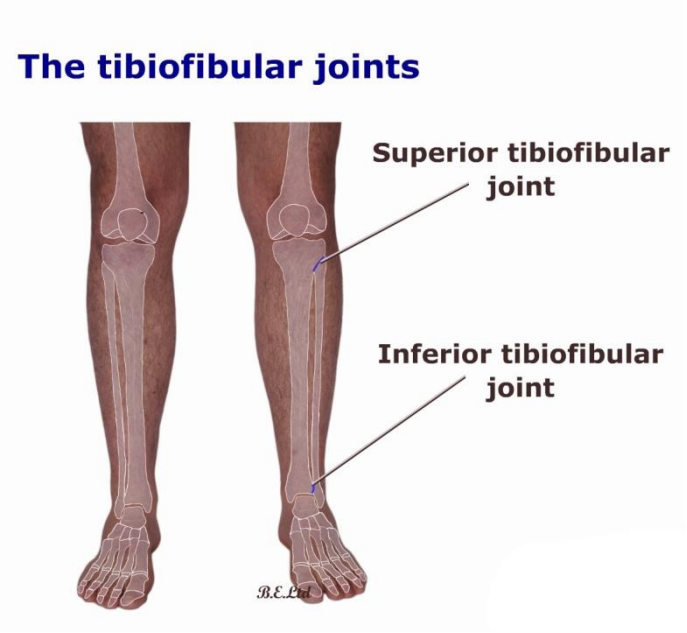

The Inferior Tibiofibular Joint

- This fibrous syndesmosis is formed by the rough, convex surface of the medial side of the lower end of the fibula, and a rough concave surface on the lateral side of the tibia.
- Like its superior counterpart this joint cannot be palpated as it is located deep within the tibia. The joint lies about 3cm above the tip of the lateral malleolus.

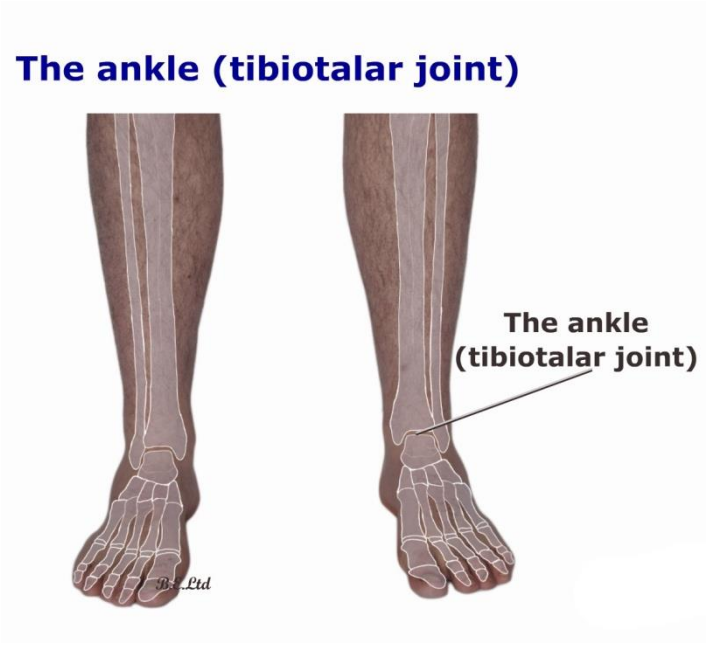

The Tibiotalar Joint

- The tibiotalar or talocrural joint forms the main component of the ankle joint. It is a synovial hinge joint that connects the distal ends of the tibia and fibula with the proximal end of the talus. The articular surfaces of the tibia and talus are concealed between the malleoli.
- The most superior part of the talar surface is on a horizontal line 2 cm above the medial malleolus.
- The anterior part of the articularsurface of the talus can be exposed when the foot is taken into full plantarflexion.

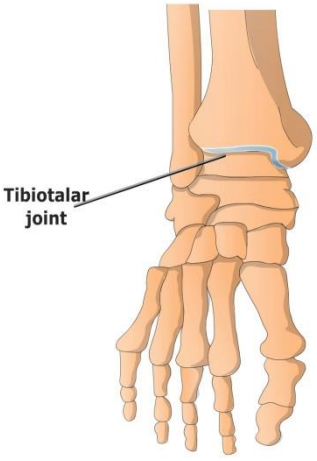

The Talo-Navicular Joint

- This is a synovial modified ball and socket joint. On the medial and inferior aspect of the mid foot locate the tubercle of the navicular. This protrusion 2.5cm anteriorly and inferiorly to the tip of the medial malleolus.
- The joint line can be traced as a curve slightly convex anteriorly. The middle of the joint line is about 3cm anterior to the medial malleolus.

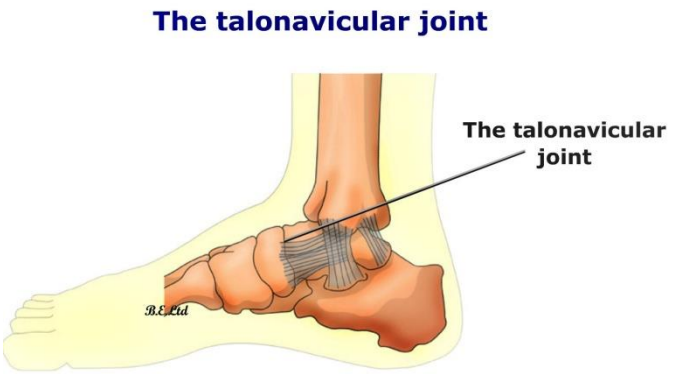

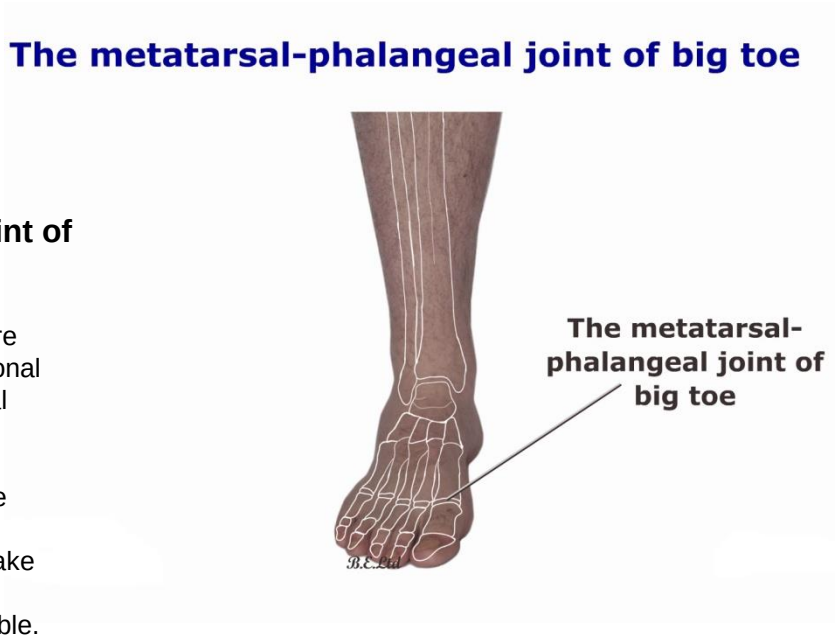

The Metatarsal-Phalangeal Joint of the Big Toe

- The metatarsal-phalangeal joints share many common anatomical and functional properties to the metacarpo-halangeal joints.
- For the big toe, grasp the length of the metararsal with one hand and the 1st proximal phalanx with the other and take the hallux into flexion and extension. Accessory movements are also possible.

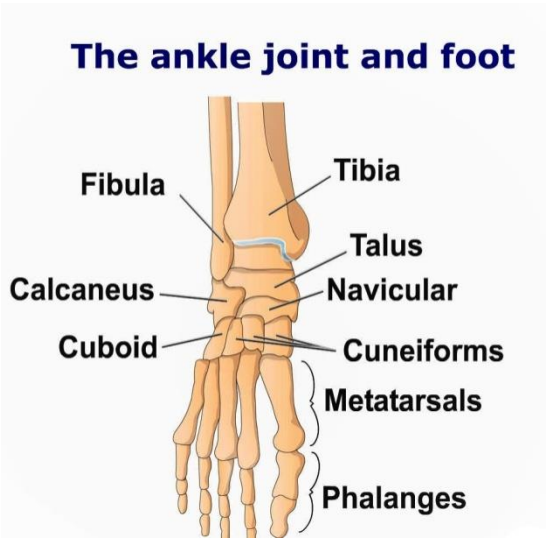

References

References and bibliography

Field's anatomy, palpation and surface markings, D Field J O Hutchinson, Elsevier.

Surface anatomy, J S P Lumley, Churchill Livingstone.

A Concise Colour Guide to Clinical Surface Anatomy, M R Borley, Manson Publishing.

Gray's Anatomy, Williams and Warwick, Saunders.

Wikipedia online encyclopaedia

Author: Andreas Syrimis
Illustrations, graphic design and photography: Annabel King, Pascalis Spyrou
Clinical editors: Charles Goillandeau, Claire Rother, Katie Stock, Euan MacLennan