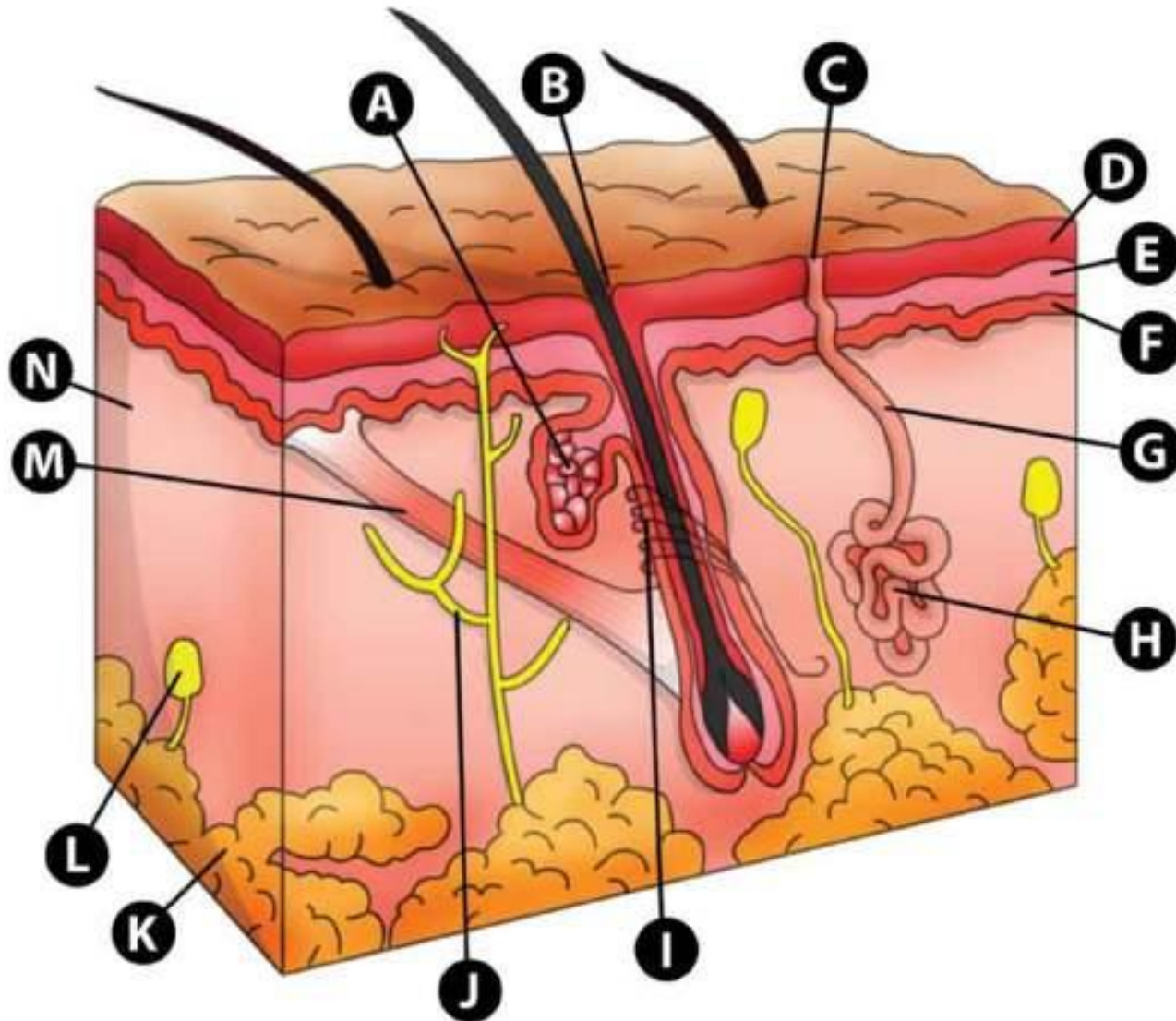


SKIN STRUCTURE

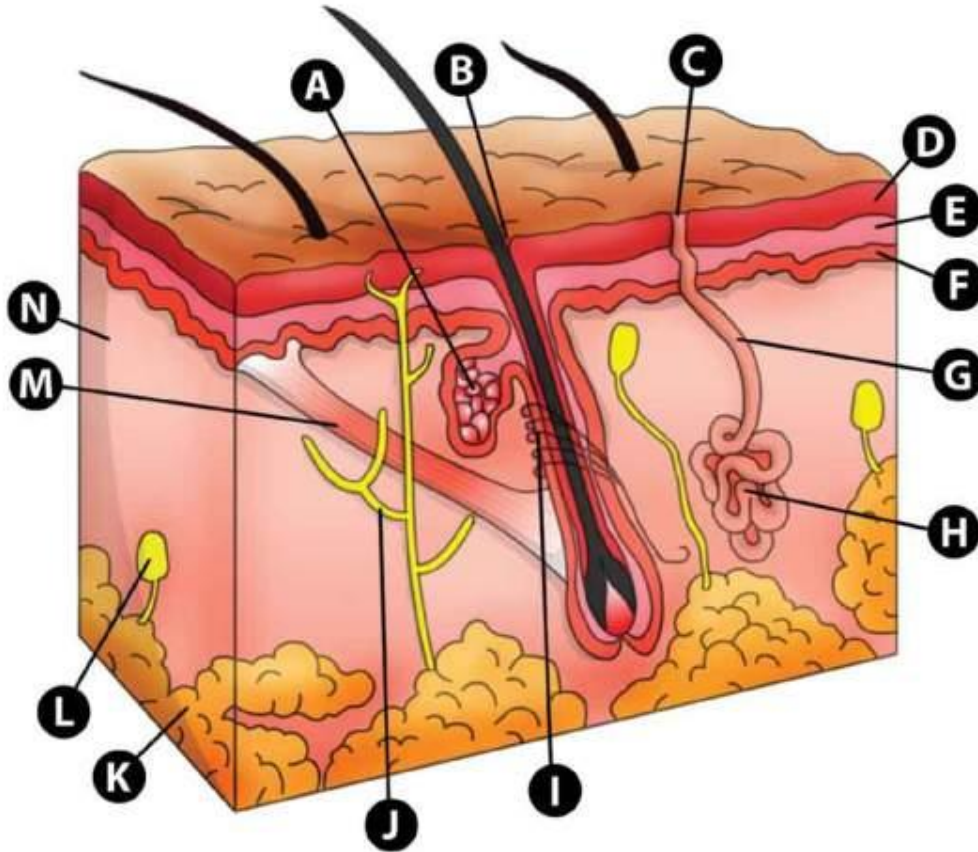
**ON THE NEXT IMAGE IDENTIFY
THE FOLLOWING STRUCTURES**

- A. SEBACEOUS (OIL) GLAND
 - B. HAIR SHAFT
 - C. PORE OF SWEAT GLAND
 - D. STRATUM CORNEUM
 - E. STRATUM SPINOSUM
 - F. STRATUM BASALE
 - G. DUCT OF SWEAT GLAND
- A. HAIR ROOT PLEXUS
 - B. FREE NERVE ENDING
 - C. SUBCUTANEOUS FAT
 - D. LAMELLATED (PACINIAN) CORPUSCLE
 - E. ERECTOR PILI MUSCLE
 - F. DERMIS

THE SKIN



THE SKIN



- A. SEBACEOUS (OIL) GLAND
- B. HAIR SHAFT
- C. PORE OF SWEAT GLAND
- D. STRATUM CORNEUM
- E. STRATUM SPINOSUM
- F. STRATUM BASALE
- G. DUCT OF SWEAT GLAND
- H. SWEAT GLAND
- I. HAIR ROOT PLEXUS
- J. FREE NERVE ENDING
- K. SUBCUTANEOUS FAT
- L. LAMELLATED (PACINIAN) CORPUSCLE
- M. ERECTOR PILI MUSCLE
- N. DERMIS

The image features a light gray background with a subtle, circular, grid-like pattern centered in the upper half. The corners of the image are decorated with several realistic water droplets of varying sizes, each with a soft shadow and a highlight, giving them a three-dimensional appearance. The word "END" is centered in the lower half of the image in a bold, black, sans-serif font.

END