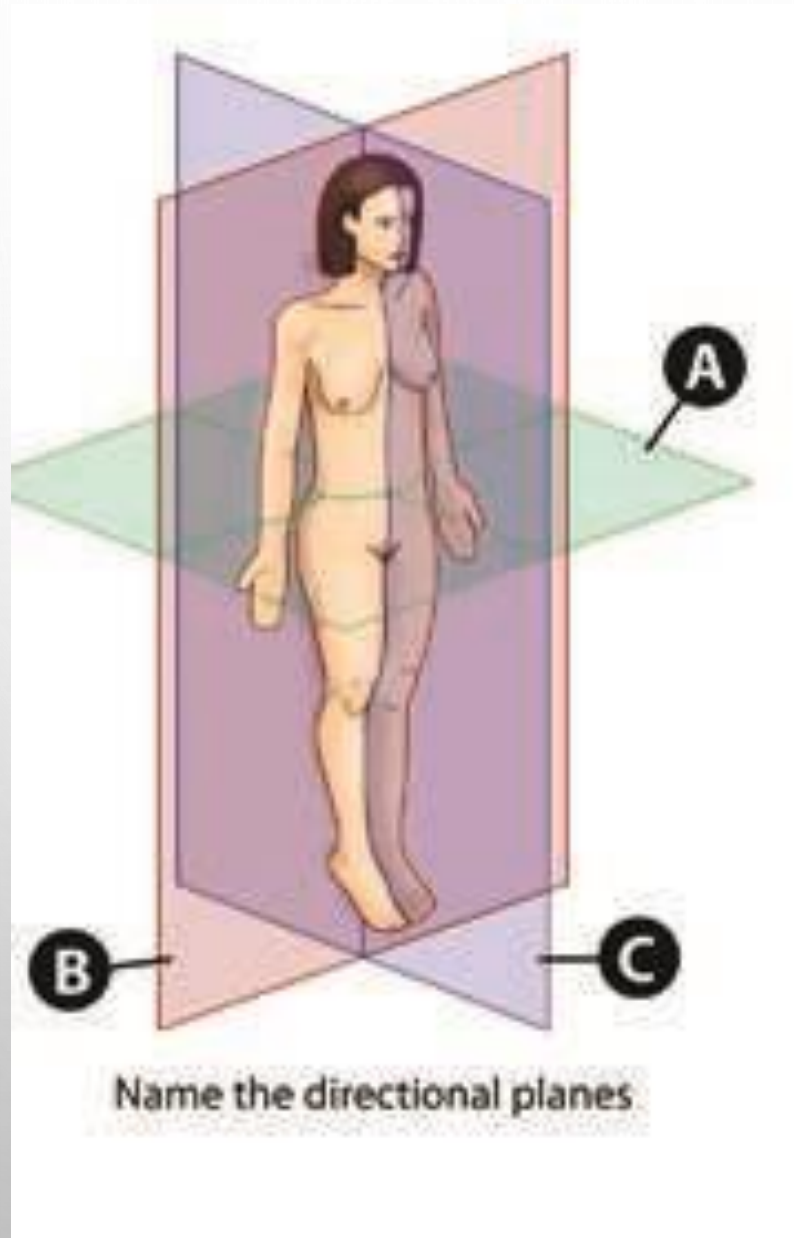




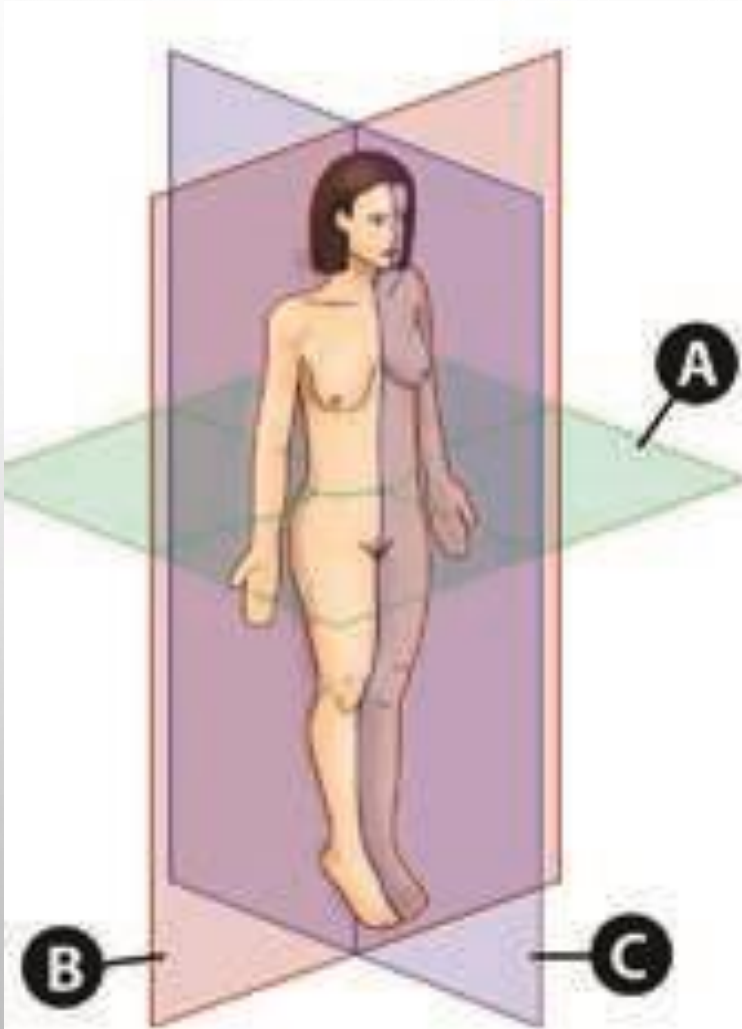
TERMINOLOGY OF ANATOMICAL PLANES

- IDENTIFY ALL THE LABELS ON THE FOLLOWING
SERIES OF IMAGES

DIRECTIONAL ANATOMICAL PLANES



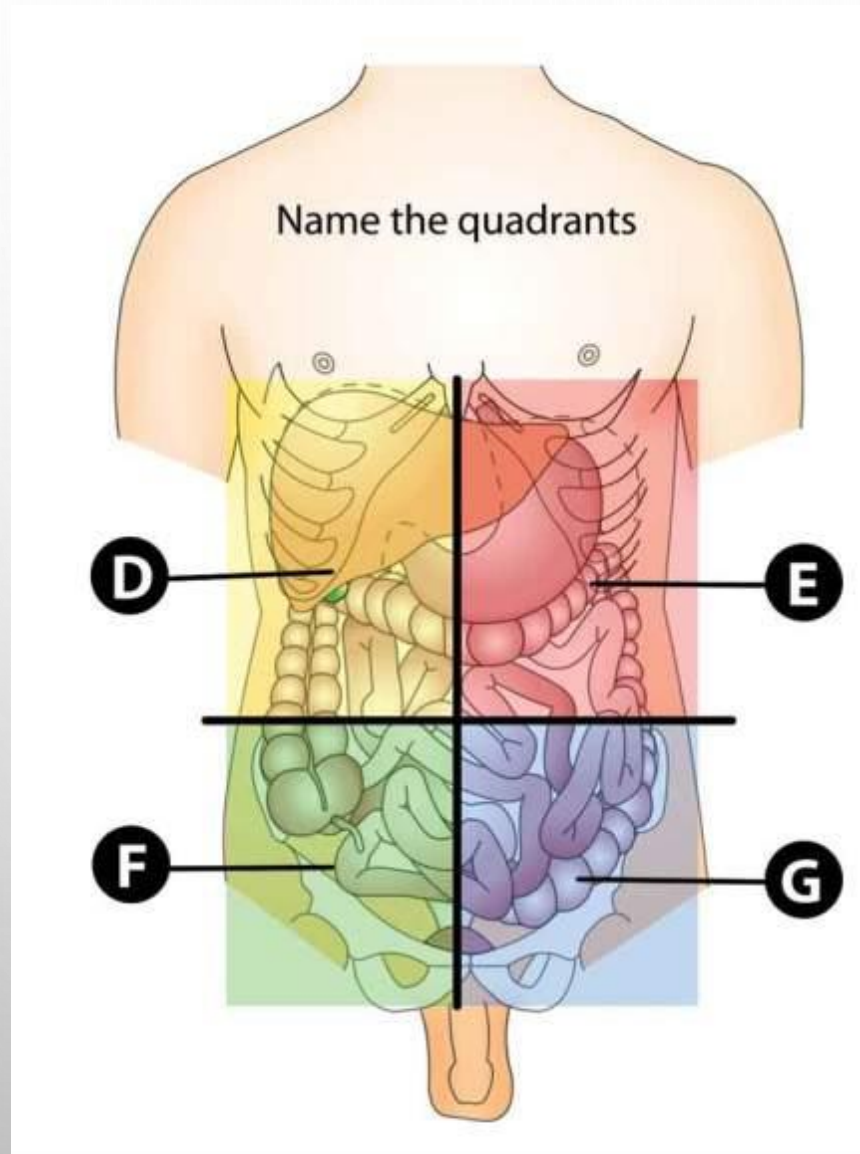
DIRECTIONAL ANATOMICAL PLANES



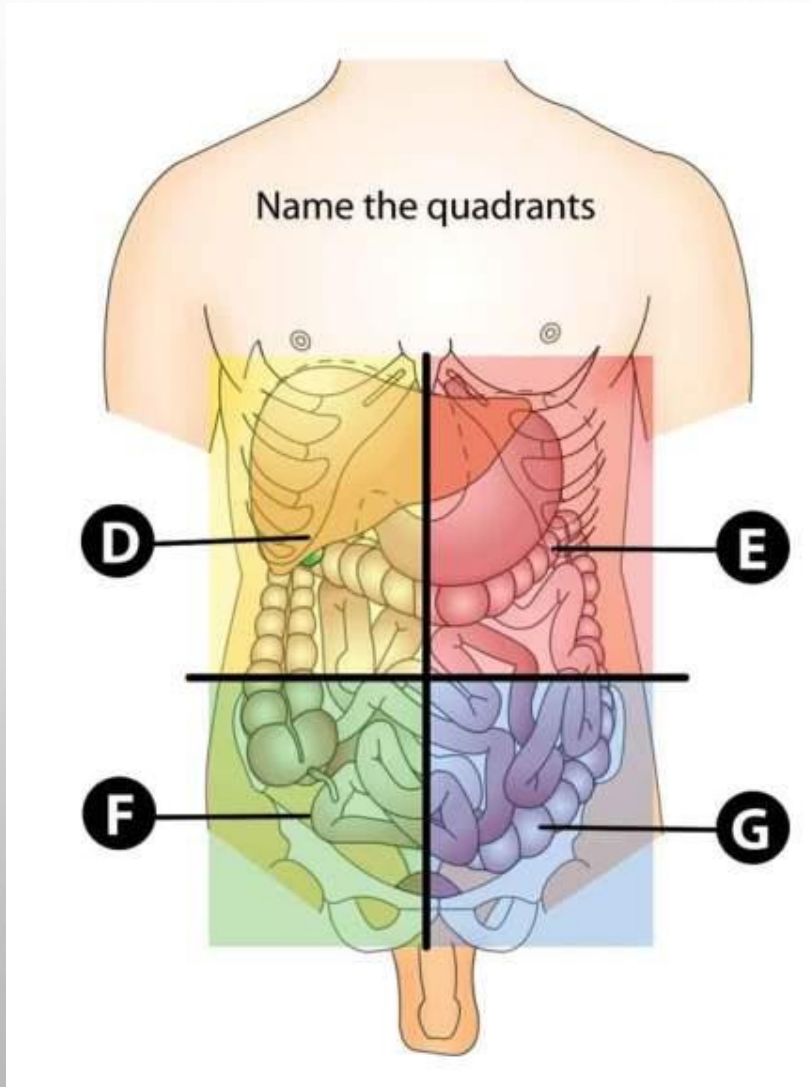
- A. TRANSVERSE / HORIZONTAL
- B. CORONAL
- C. SAGGITAL

Name the directional planes

ABDOMINOPELVIC QUADRANTS



ABDOMINOPELVIC QUADRANTS



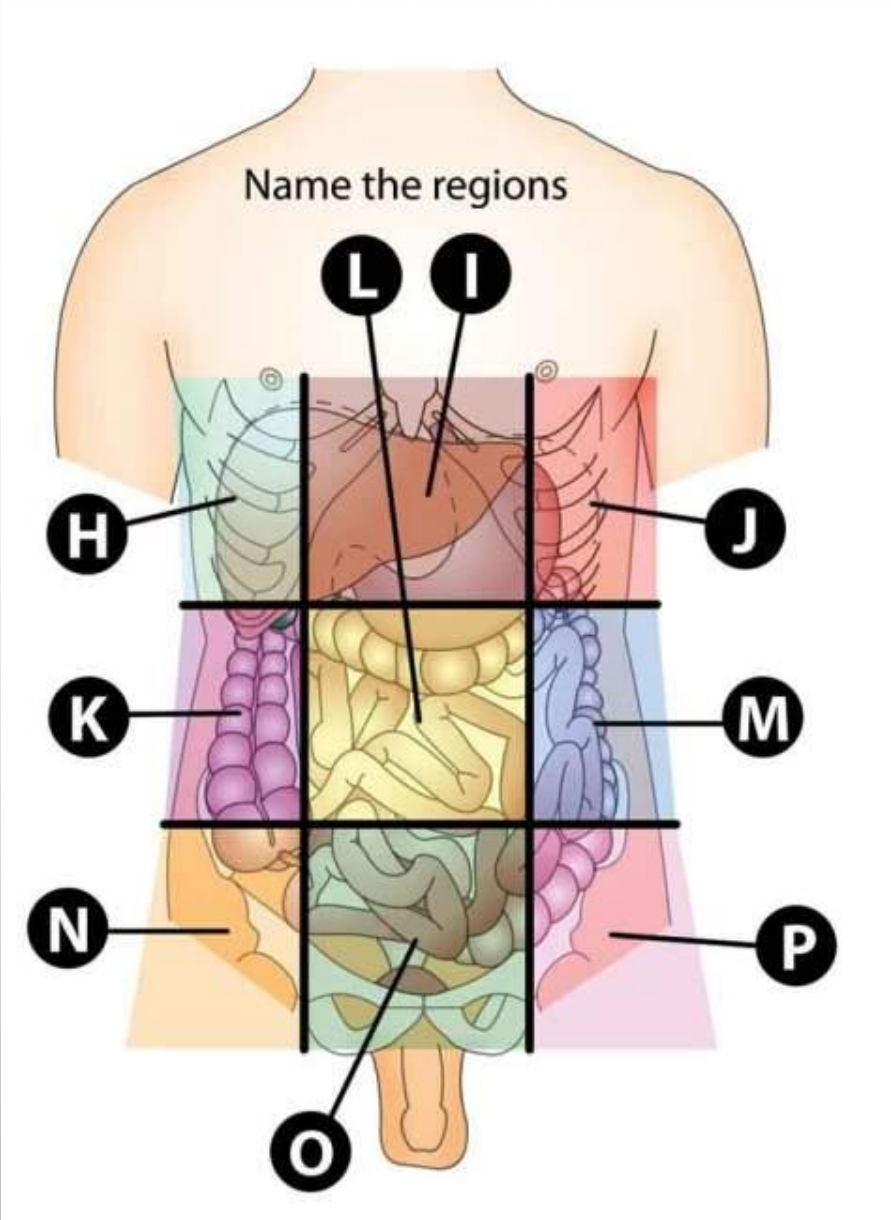
D. RIGHT UPPER QUADRANT

E. LEFT UPPER QUADRANT

F. RIGHT LOWER QUADRANT

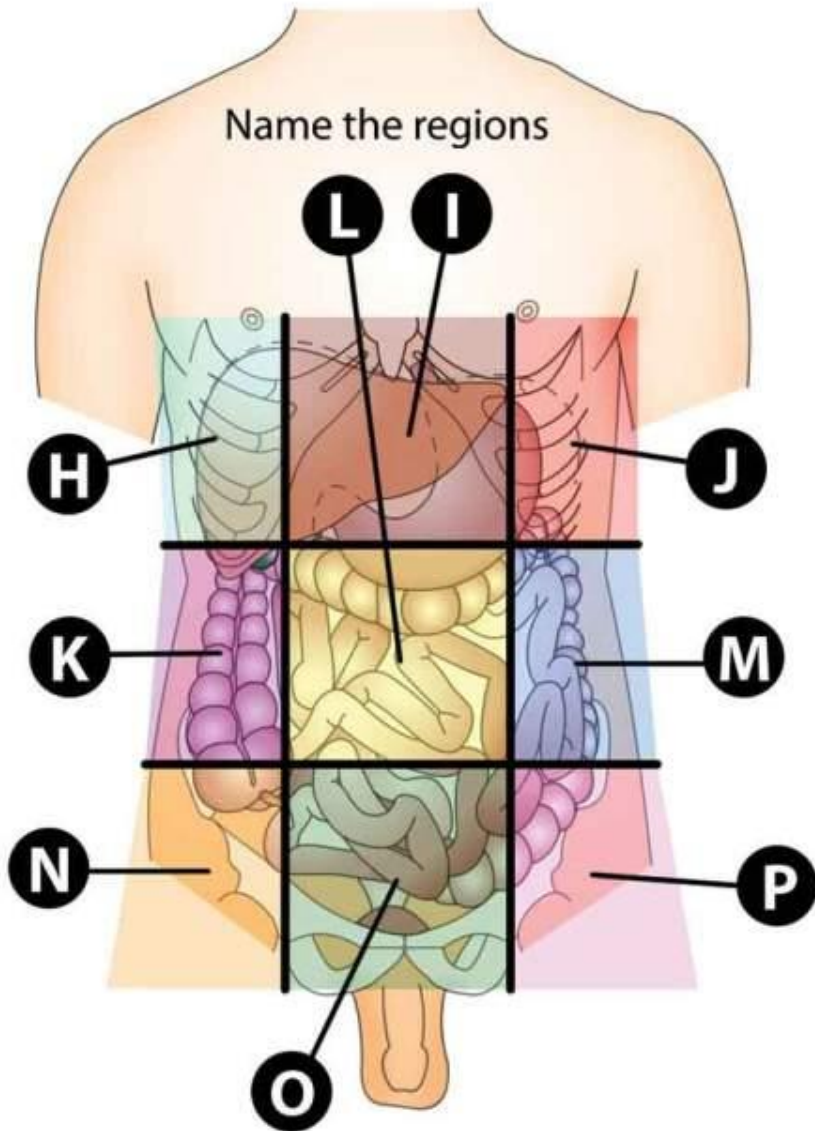
G. LEFT LOWER QUADRANT

ABDOMINOPELVIC REGIONS



ABDOMINOPELVIC REGIONS

Name the regions



- H. RIGHT HYPOCHONDRIAC
- I. EPIGASTRIC
- J. LEFT HYPOCHODRIAC
- K. RIGHT LUMBAR
- L. UMBILICAL
- M. LEFT LUMBAR
- N. RIGHT PELVIC / INGUINAL / ILIAC
- O. PUBIC / HYPOGASTRIC
- P. LEFT PELVIC / INGUINAL / ILIAC

The image features a light gray background with several realistic water droplets of various sizes scattered across it. The droplets are rendered with soft shadows and highlights, giving them a three-dimensional appearance. In the center of the image, the word "END" is written in a bold, black, sans-serif font.

END